

November 7, 1988

Robert C. Carr, M.D., F.A.C.S.
Orthopaedic Surgery

James C. Gaskette, R.N., S.A.
Clinical Assistant

Thomas Mester
Attorney at Law
Seventh Floor Engineers Building
Cleveland, Ohio 44114

Re: Cheryl
File No. T-45838
DOI: 4/29/86

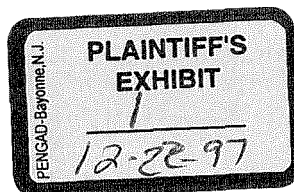
Dear Mr. Mester:

I am writing to you in follow-up to the above patient who has been under my care since 11/6/86.

Since my last letter to you dated December 8, 1986, Cheryl has been seen on a regular basis. She has gone through the Meridia Huron Hospital Chronic Pain Management Program with essentially no improvement in her symptoms. I have run her through a variety of diagnostic testing, including an MRI scan of her cervical spine, a CT scan of her lumbosacral spine and an EMG evaluation of her upper extremities. These tests failed to show any herniated disc although the CT scan of her LS spine showed a mild bulging annulus at the L4 level as well as a central protrusion at the L5 level. The nerve conduction studies that were performed by Dr. Joseph Zayat, a neurologist, revealed "possible C8-T1 cervical radiculopathy".

Despite all conservative invasive and non-invasive methods, we have been totally unsuccessful in relieving the vast majority of Cheryl's complaints of intermittently severe chronic neck and upper back pain, as well as low back pain. Recently, I sent her to Dr. Peter Poulos, a neurosurgeon, who evaluated her. Apparently, according to Cheryl, there were no additional findings made by this physician. Cheryl has been evaluated by experts in the fields of orthopaedic surgery, radiology, neurology, as well as neurosurgery..

The long term prognosis for this particular incident is quite poor. In all likelihood, there will never be any resolution of her symptoms. Clearly, her psychological testing shows that there has been some significant damage by this accident and has brought out possible underlying psychological pathology. It is my opinion that she will continue to need physical therapy for the rest of her life on an intermittent basis. The cost of this would be approximately 62500.00 a year. I doubt whether there will be any significant recovery or that she will ever reach a pain free status.




as Mester
Cheryl

November 7, 1988

(Page 2

It is my opinion the above described residuals of injury were a direct consequence to the motor vehicular accident in question which occurred on 4/29/86.

Sincerely,



Robert C. Corn, M.D., F.A.C.S.

RCC/mkm